



**MDU**



**WESLEYAN  
MEDICAL SICKNESS**

# **Presenting Skills – Practice Examples**

Dr Will Dooley & Dr Andy Smith



# How to use

Use the following slides to have focused practice on your presentation skills.

This is best done with a work partner so you can present the cases to each other

Print each slide out to be able to jumble the order of the cases

Then take one of the cases, study the signs shown on the slide (you can assume there are no other signs found with the patient)

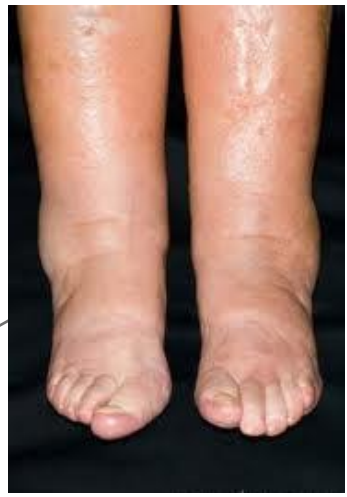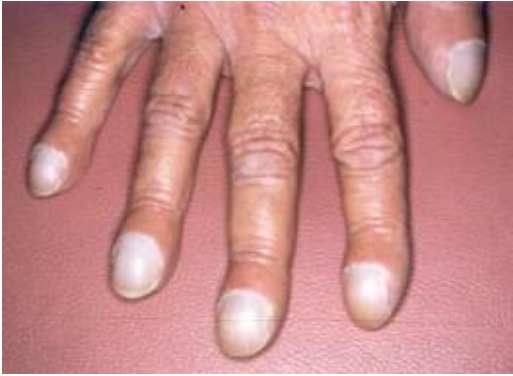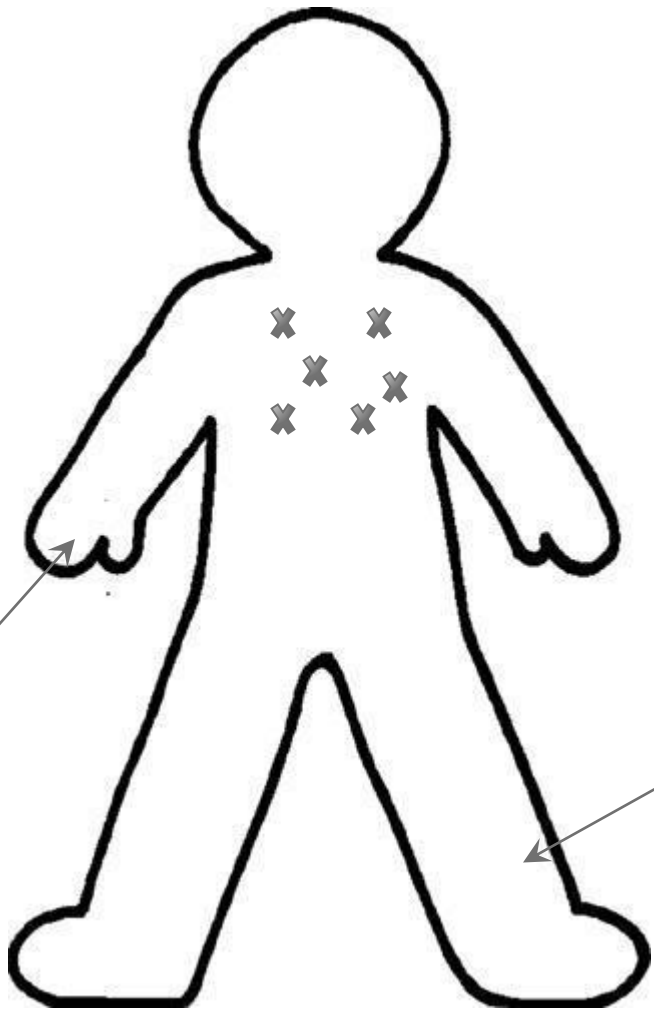
Then take a minute to formulate your thoughts and then present the case to your partner.

After completing these, make some of your own to practice the other common presentations

***PLEASE SEE THE SIMPLY FINALS LECTURE,  
“PRESENTING AND HANDOVER” FOR MORE TIPS.  
Available at: [www.simplyrevision.org.uk/cardiology.html](http://www.simplyrevision.org.uk/cardiology.html)***

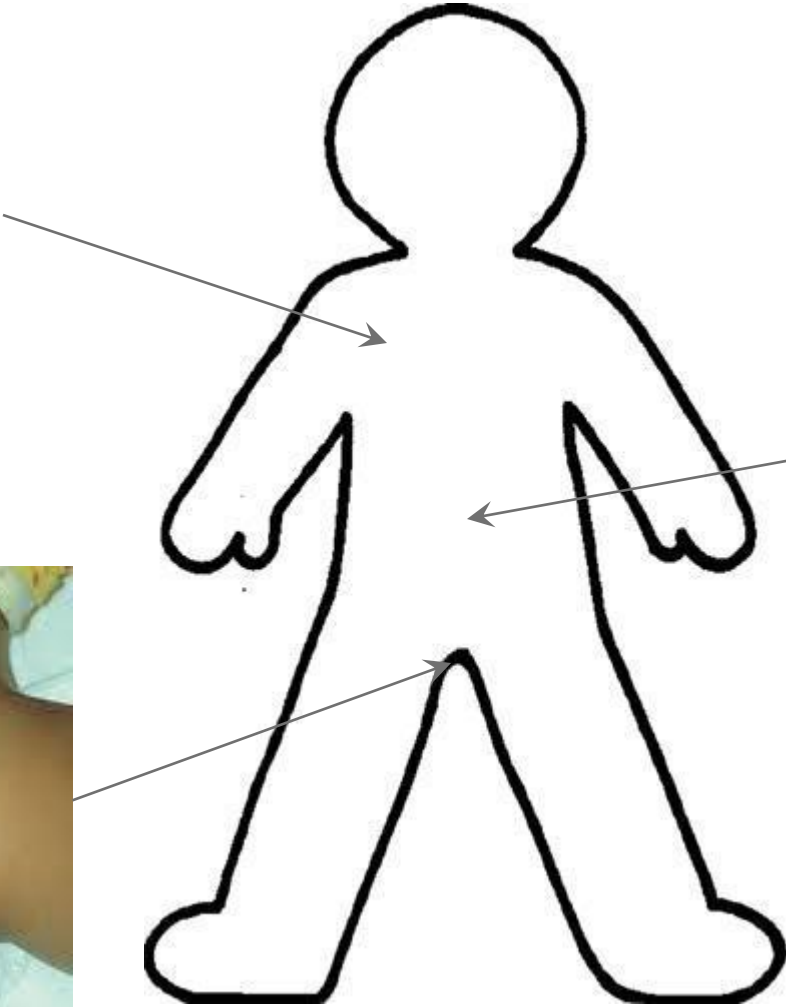


Examine Respiratory System of this 50 yo who suffered several episodes of pneumonia as a child.

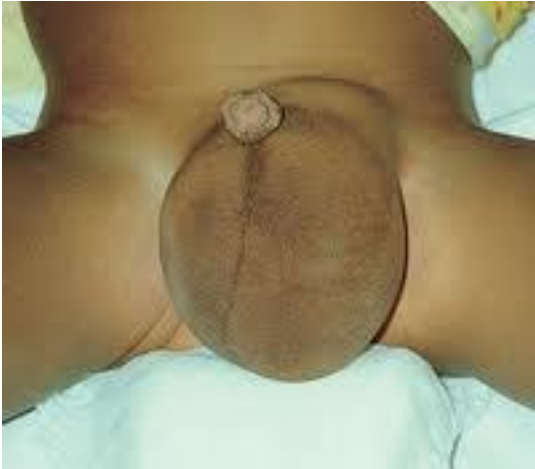

Perform an abdominal examination of this 55 yo man

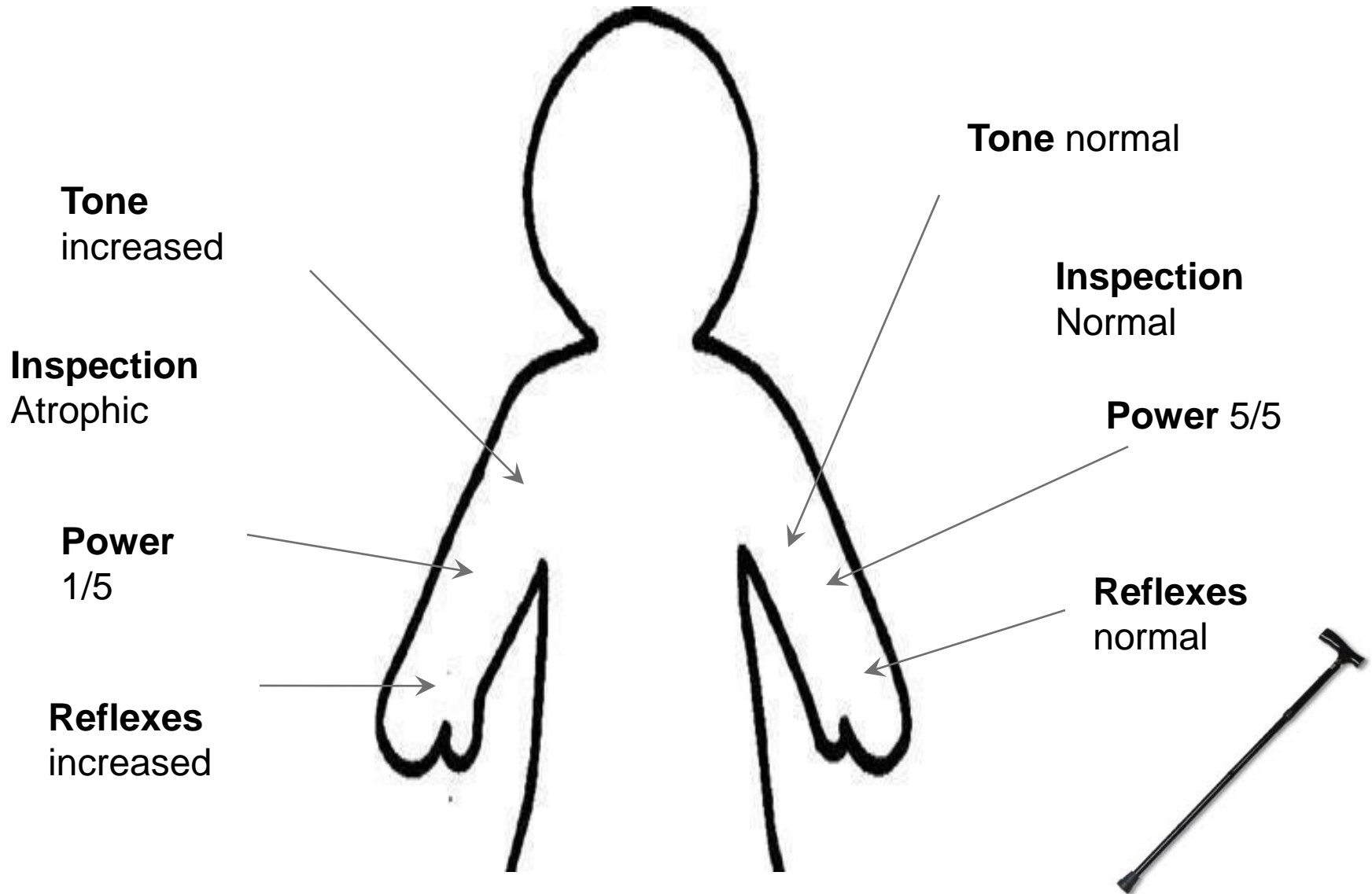
Coughing



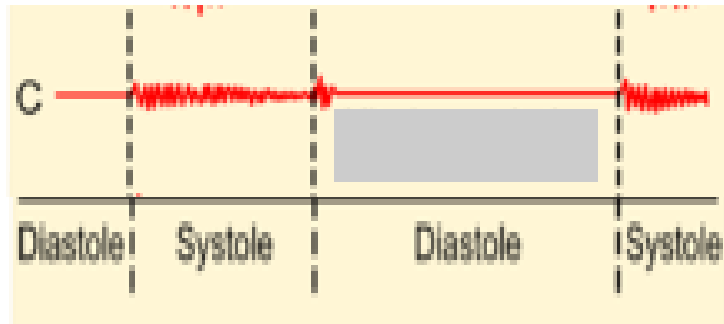
High BMI



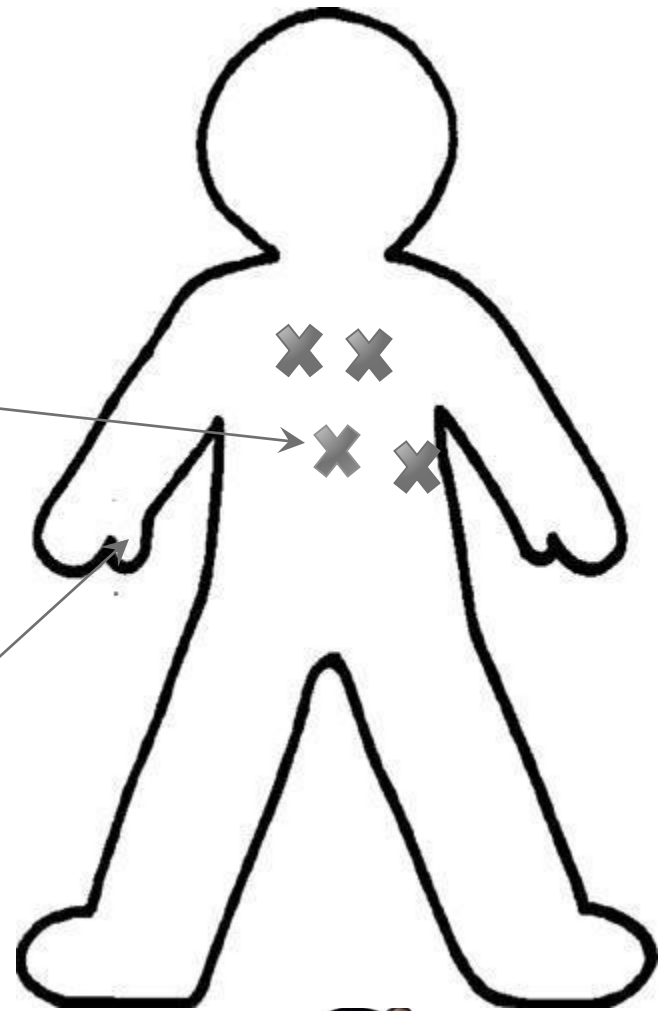
Please examine this patient's upper limbs/gait.



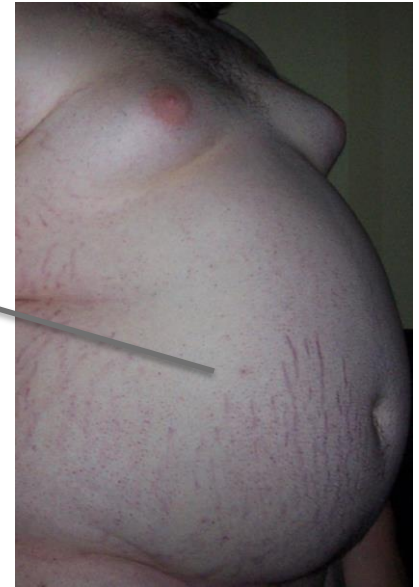
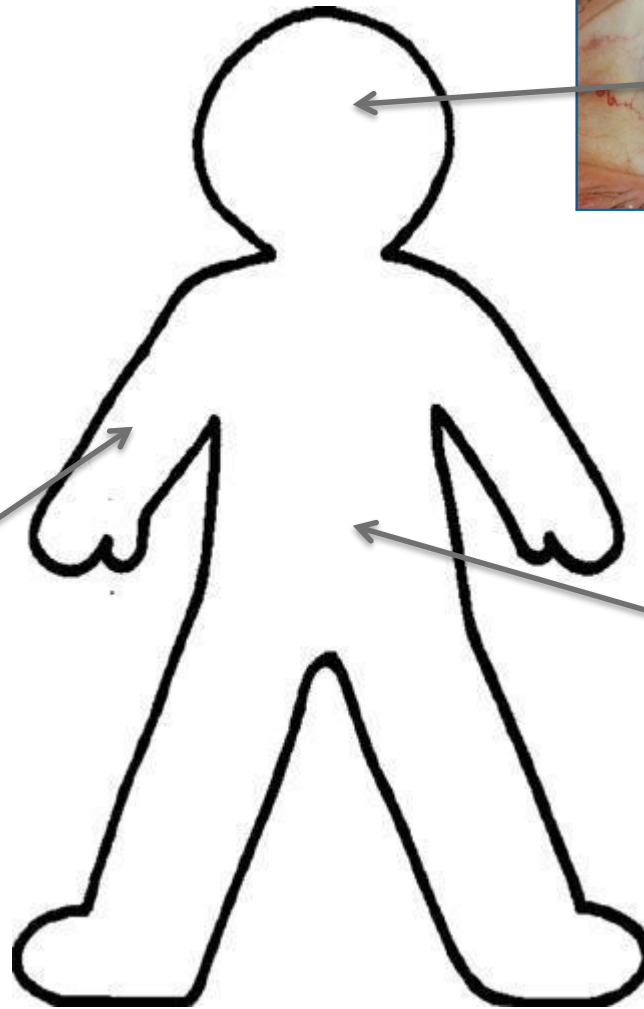
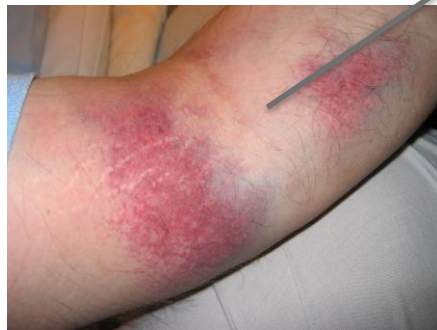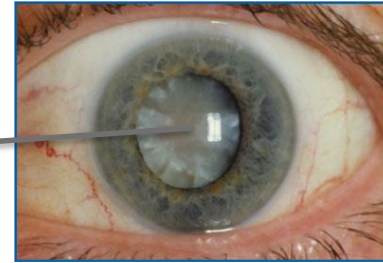
Examine the CV system of this 85yo patient.



Irregular  
Pulse

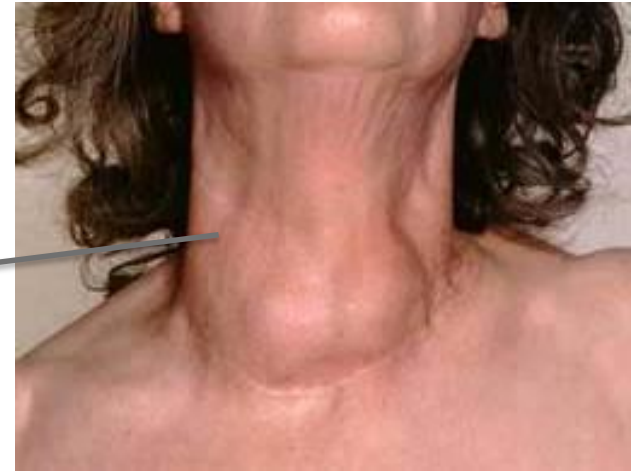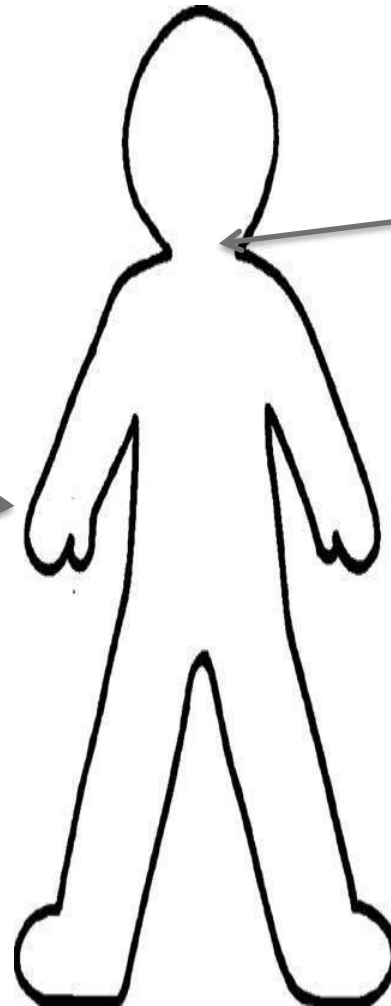


Examine this  
55yo man with a  
Long Hx of  
eczema and  
COPD



46yo female  
Feels generally  
unwell. Concerned  
about her neck.

Pulse 98



Fine tremor  
in hands



Examine Respiratory System of this 65 yo who presents with worsening cough

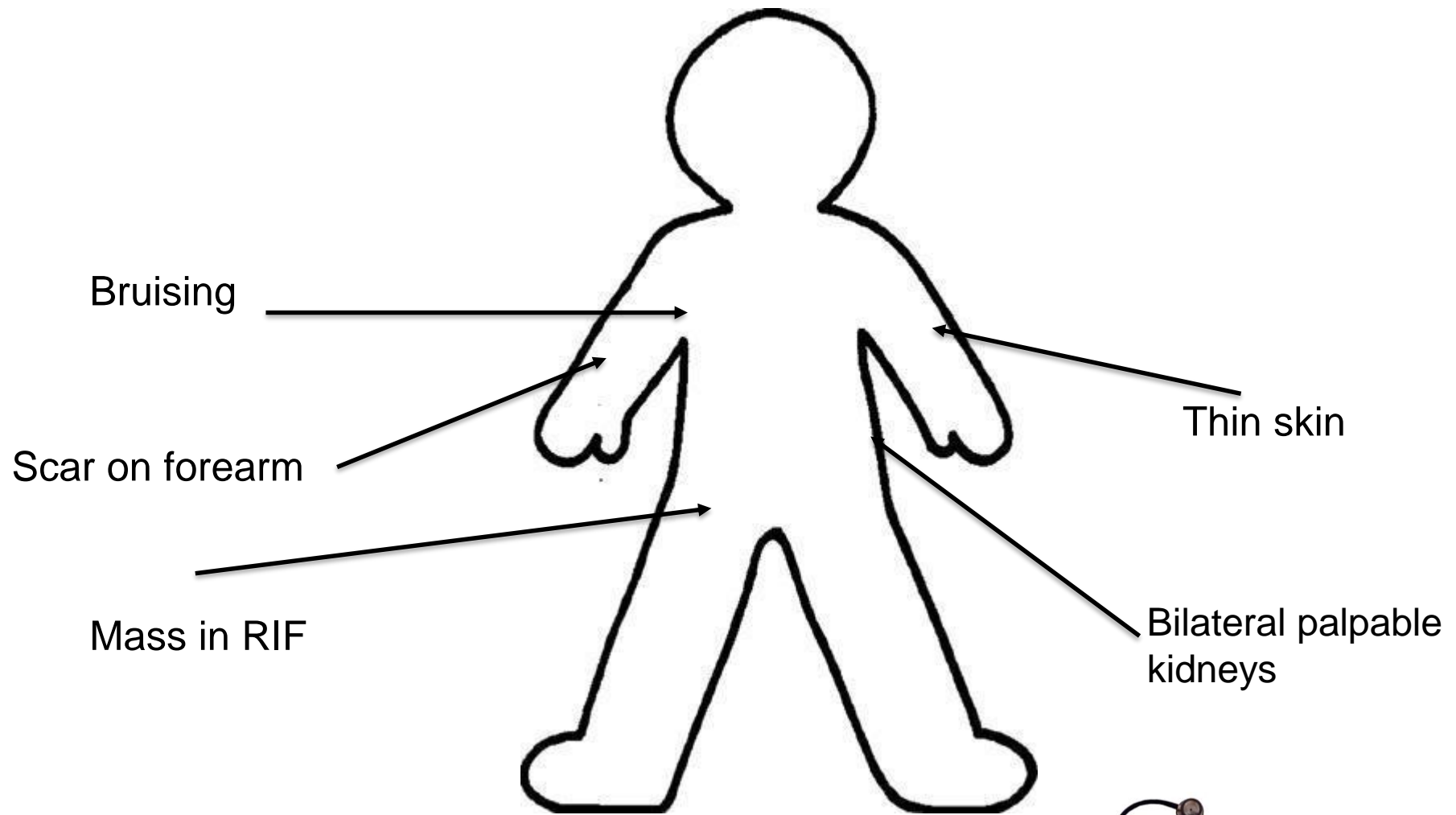


Coughing

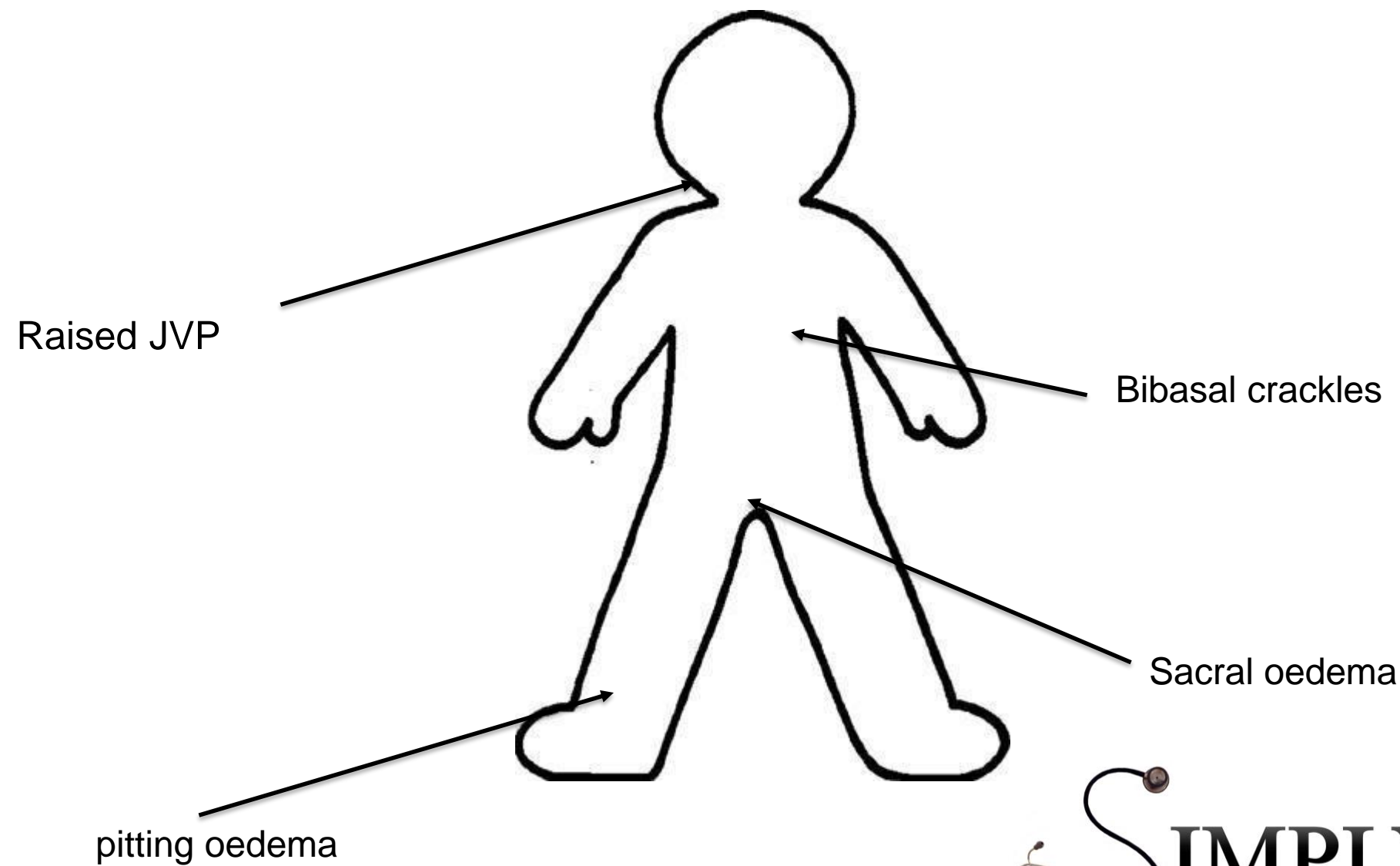


Cachectic

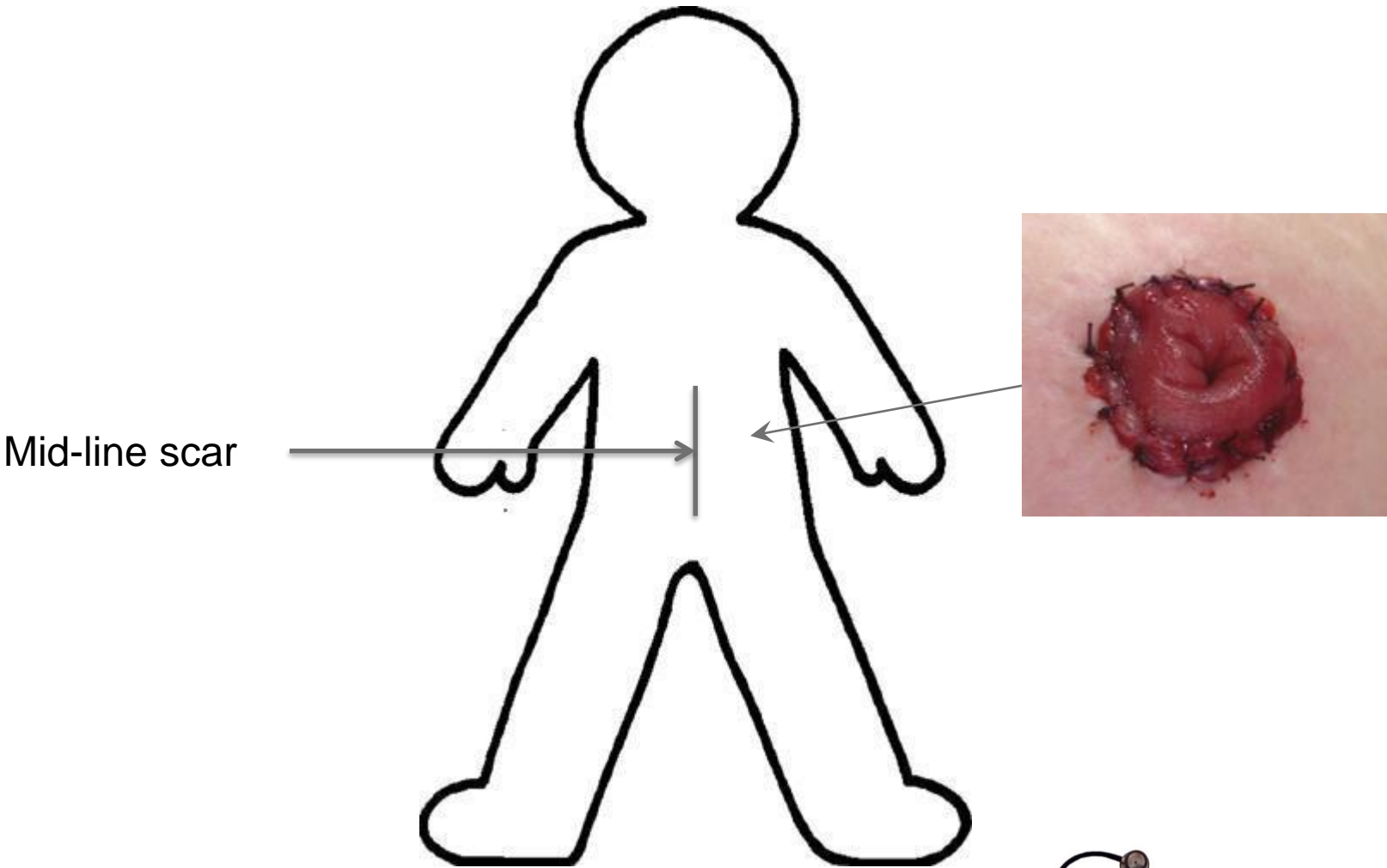
Examine abdominal system of this 50 yo gentleman.



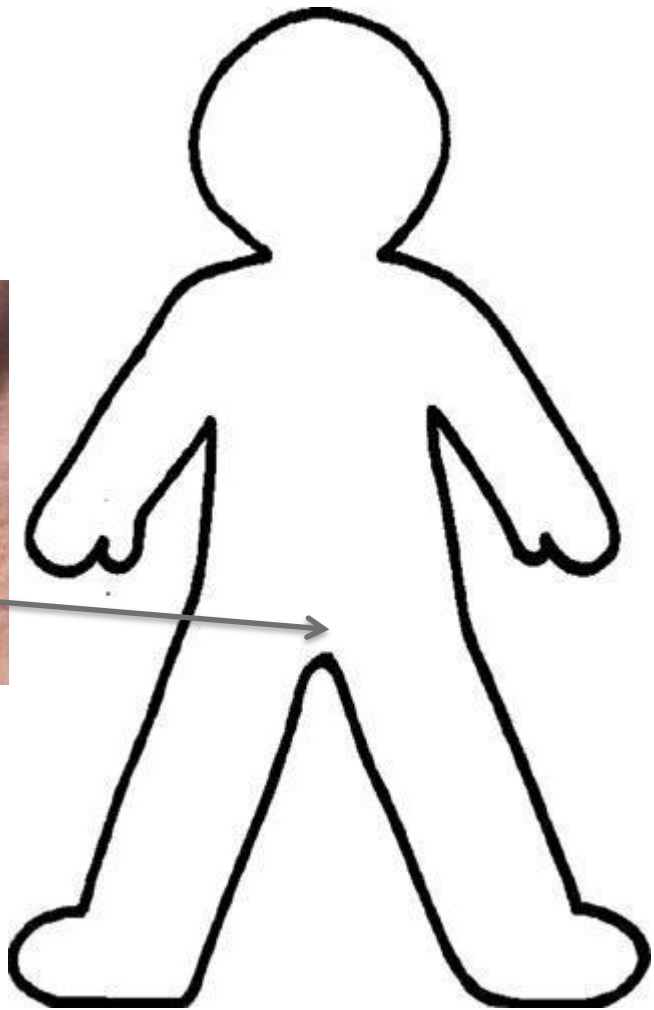
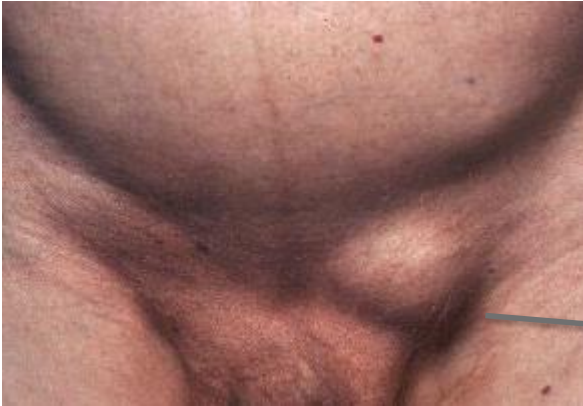Examine respiratory system of this 80 yo woman.



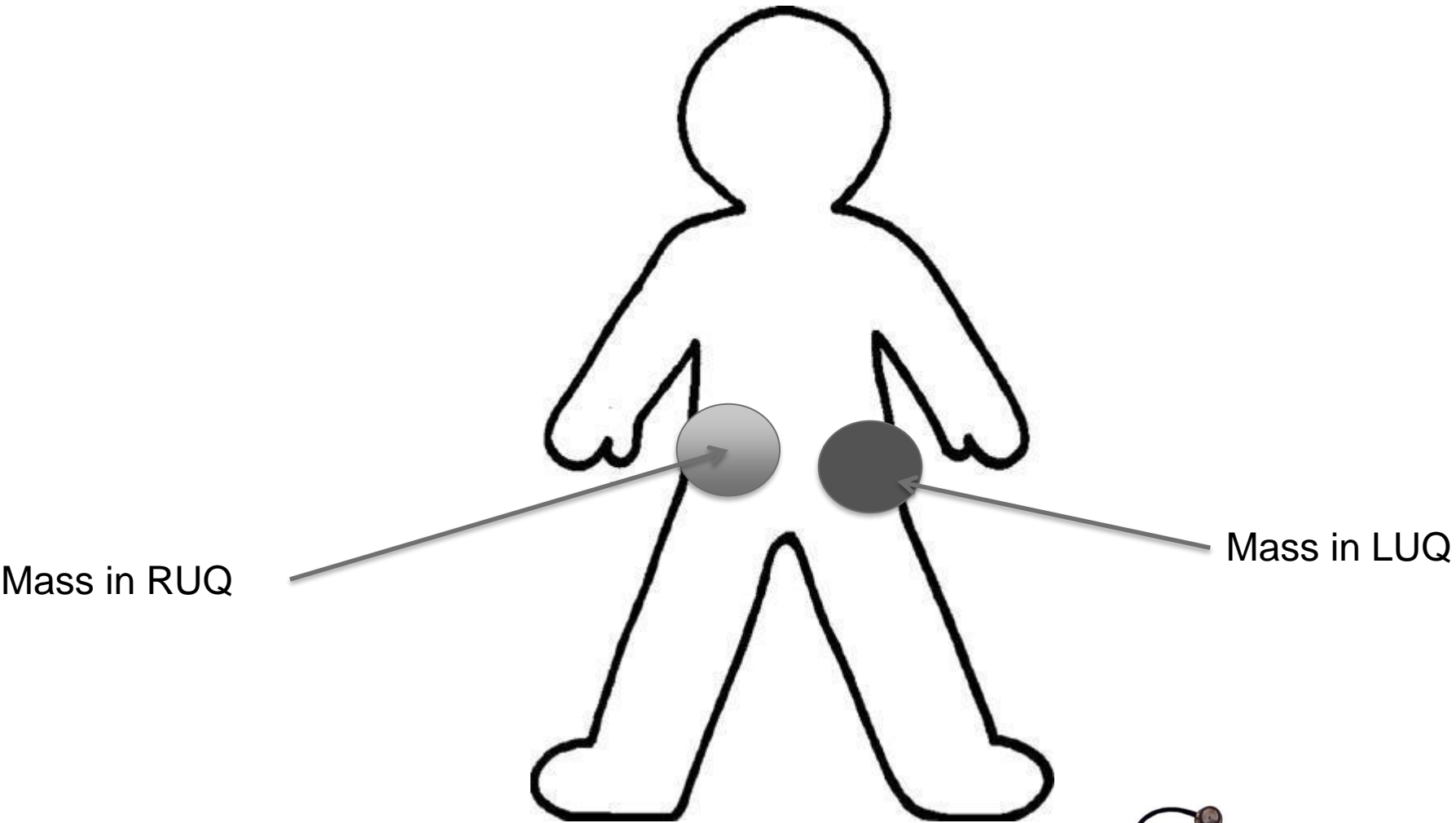
Examine the abdominal system of this 57 yo who has recently had an operation.



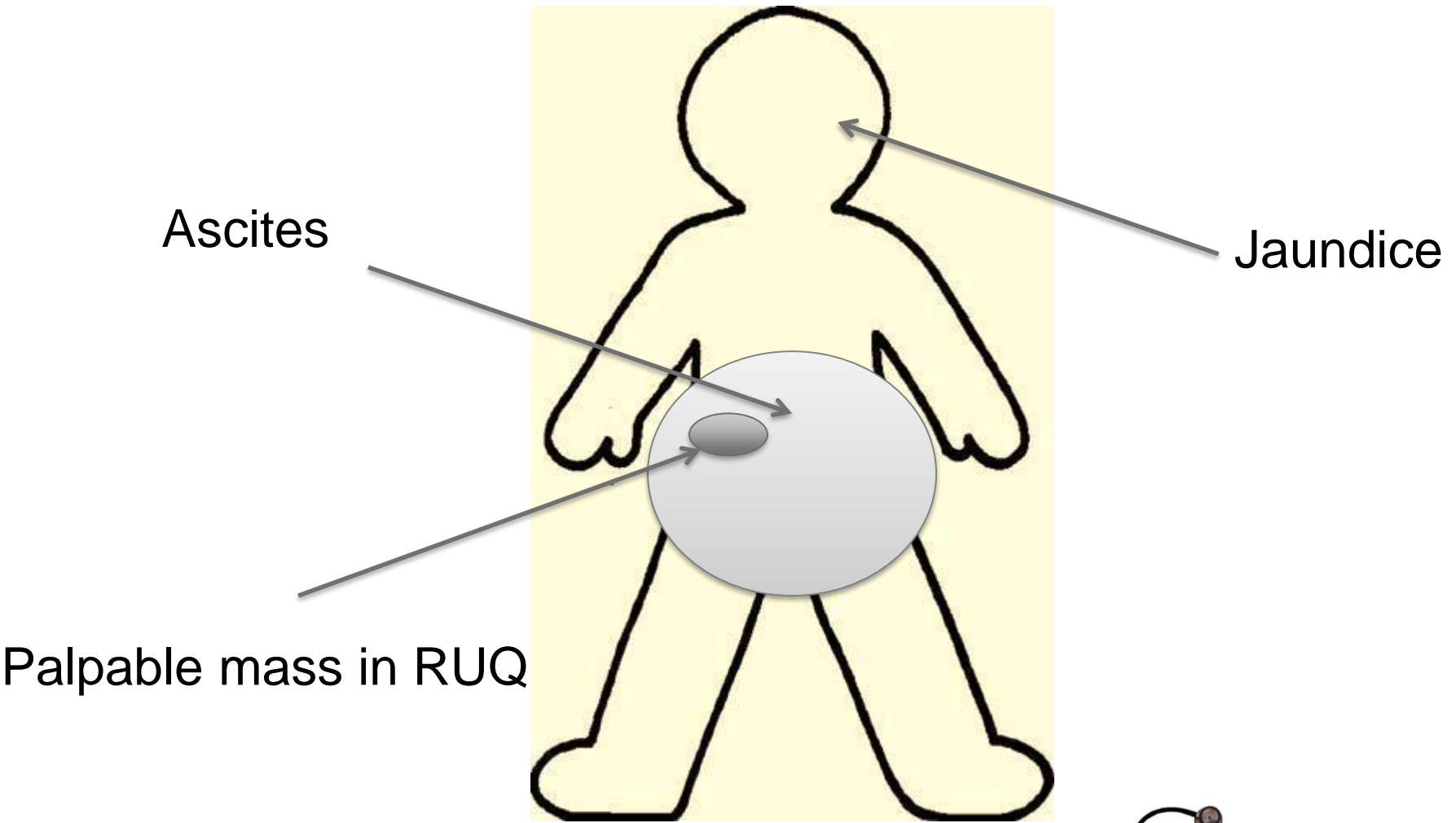
Please examine the groin of the following 35 yo patient who reports a lump



Examine GI system of this 70 yo gentleman.



Examine GI system of this 50yo IV Drug User.

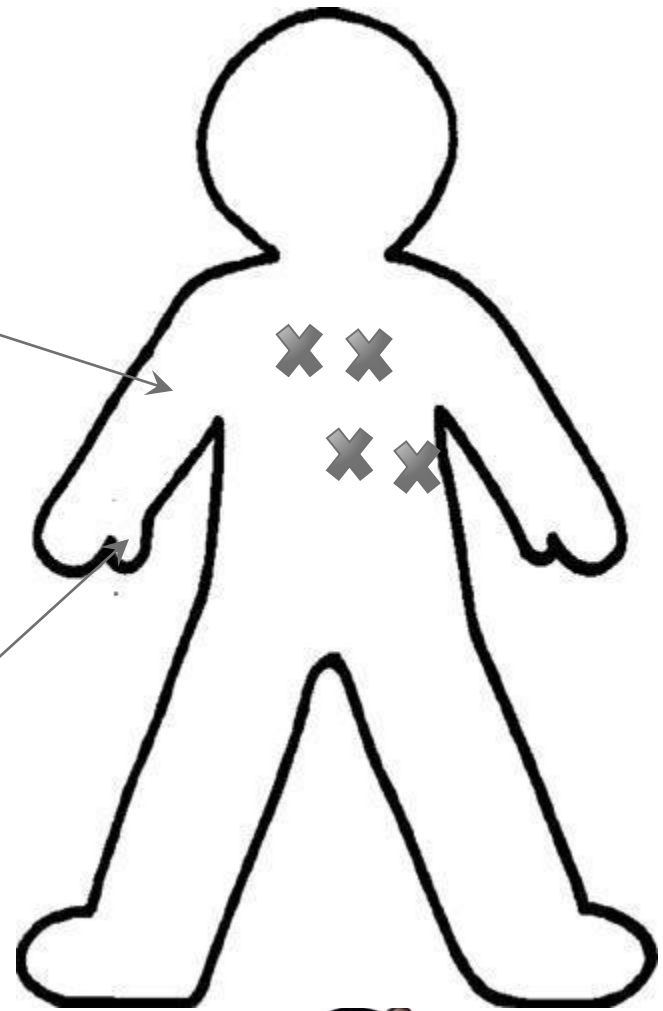


Examine the CV system of this 85yo patient.

HS I+II+0

Bruising

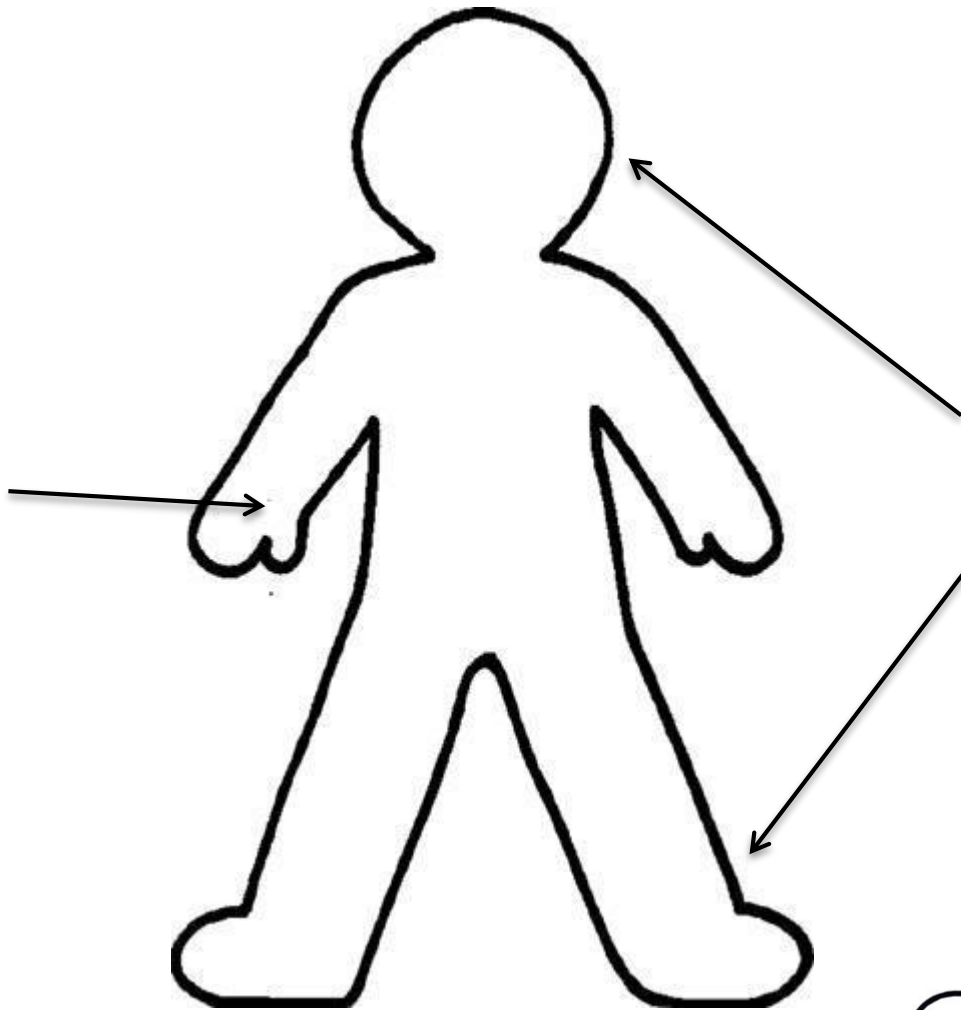
Irregularly irregular  
Pulse





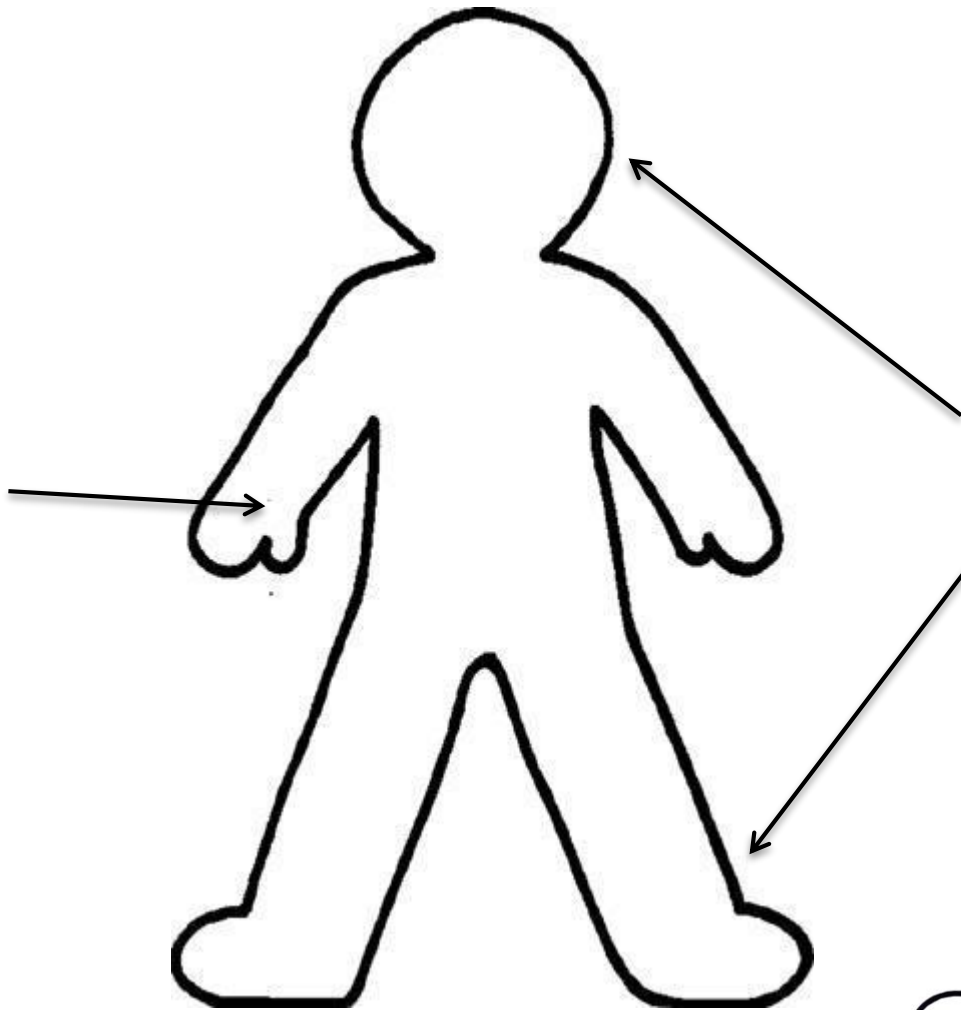
Examine neurovascular system of this 80 yo patient?

Weak atrophied  
Absent Reflexes  
Decreased tone  
Fasciculation



Left side normal

Examine neurovascular system of this 80 yo patient?



Brisk Reflexes  
Increased tone

Left side normal