

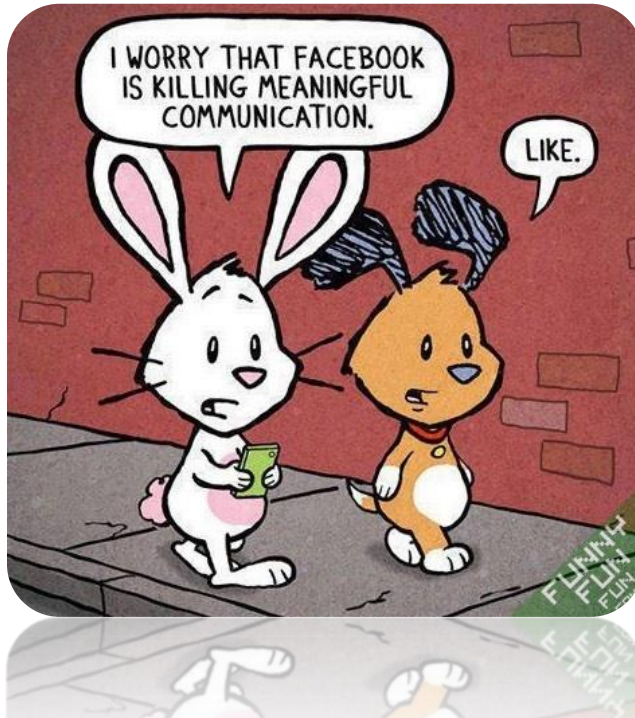Communication Skills: SBAR / Presenting

Dr Andrew Smith



Intro

- SBAR
- Summarising Histories/Examinations
- Examples
- Other Resources



SBAR

A method originally used in the Navy.
It can be used in the clinical setting for:

- Handover
 - Referrals
 - Asking for advice
-
- **S**ituation
 - **B**ackground
 - **A**ssessment
 - **R**ecommendation



SBAR

- **Situation**
 - Who and where you are
 - Brief outline of why you're calling/speaking
- **Background**
 - Objective outline of what has happened - keep it relevant
 - Past history, working diagnosis, investigations
- **Assessment**
 - Subjective thoughts on the current situation
 - What has changed, what have you done?
- **Recommendation**
 - What do you want the person to do and when?



Situation:

Hello, is that Dr Dooley? I'm Andy Smith, an ST4 doctor currently giving a lecture in the Perrin.

Background

I've been at work all day and have only managed to have a cup of tea during that time.

Assessment

Currently, my pulse is 90bpm and urine output is approximately 20mls/hour. I have dry mucosa and am developing a headache.

Recommendation

Would you be able to pop to Needoos and get me a tikka roll and a diet coke as soon as possible, please? Thank-you.



Example 1

- Patient: Doreen Jones – on Garrod Ward
- DOB: 11/2/1936
- PC: Fall secondary to a UTI and dehydration
- PMHx: Vascular Dementia, Congestive Cardiac Failure
- DHx: Aspirin, Furosemide, Ramipril
- Day 2 of admission. She has been given antibiotics for her UTI and has received 5 litres of IV fluids.
- Obs: P105 BP 130/86, RR 32 Sats 88% on air, T 36.7
- O/E: Confused but talkative. Peripheral oedema, Tachypnoeic with widespread inspiratory crackles.
- You're the FY1 on-call. What would you do initially?
- You want to call the medical registrar for advice – how would you present the case?



Situation:

Hello, I'm Andy Smith, the FY1 doctor on-call. Is this the medical registrar? I'm calling to see if you can come and review Doreen Jones, an 82 year old lady on Garrod ward who I was asked to come and see by the nurses as she has become very breathless.

Background

She presented two days ago after a fall and has been receiving IV fluids and antibiotics for a UTI. She is known to have vascular dementia and heart failure and usually takes Aspirin, Furosemide and Ramipril.

Assessment

Currently, her pulse is 105 and regular, blood pressure 130/86, respiratory rate 32 and she is saturating 88% on air. She is afebrile. On examination, there is some peripheral oedema and some widespread inspiratory crackles in the chest. I think she is fluid overloaded and has pulmonary oedema. I have put her on some high-flow oxygen, stopped the IV fluids and prescribed a stat dose of IV Furosemide.

Recommendation

Is there anything else I should do? Would you be able to come and review her in the next 15 minutes, please? Thank you.

What else could you do?



Example 2

- Patient: Alfred Banks – just brought into resus by L.A.S.
- DOB: 26/1/1931

- PC: 3/7 history of a rash on the left foot
- PMHx: T2DM, Hypertension
- DHx: Metformin, Gliclazide, Amlodipine

- Obs: P135, BP 92/45, RR 23 Sats 96% on 2L, T 38.6.
Cap. Glucose 13.4

- O/E: confused and agitated, erythematous and swollen left foot.
Dry mucous membranes, JVP not visible. Irregularly irregular pulse.

- What would you do initially?
- You need to refer to the medical registrar – how would you present the case?



Situation:

Hello, I'm Andy Smith, one of the E.D. FY2s. Is this the medical registrar? I'm calling to refer Alfred Banks, an 87 year old gentleman who has presented to E.D. with sepsis, likely secondary to a left foot cellulitis.

Background

He is a gentleman with a past medical history of T2DM and hypertension controlled with Metformin, Gliclazide and Amlodipine. He has a 2 day history of worsening redness, swelling and pain of the left foot.

Assessment

Currently, he has a pulse of 135 and appears to be in Atrial Fibrillation. He has a BP of 92/45, his temperature is 38.6°C and resp rate 23 but is saturating well on 2L of oxygen. He is confused and agitated and seems dehydrated with evidence of cellulitis of the left foot. We have taken bloods and cultures, started antibiotics, have given a fluid challenge and started maintenance fluids.

Recommendation

Would you be able to come and review the patient as soon as possible, please? Is there anything else you would like me to do now?

Thank-you

What else could you do?



History/Examination Presentations

- You will need to summarise your histories and examinations in the OSCEs
- You can take a moment to collect your thoughts – don't feel the need to rush in and waffle.
- DON'T PANIC
- Keep it structured - Keep it simple
- You can start with a summary of the patient moving onto more detail
- Only state important positives and negatives – it is not a comprehensive list of everything you've found
- Give a one line summary at the end



History/Examination Presentations

- Be prepared to give a differential diagnosis, investigation and management options
- Again, DON'T PANIC
- Say common conditions before rare things
- There are only so many things you're going to need to remember!
E.g.:
 - Full History and Examination
 - Bedside tests: ECG, PEFr, ABG, Urine Dip
 - Lab Tests: FBC, U+Es, LFTs, TFTs
 - Radiology: X-rays, US, CT, MRI
- If the patient is unwell: stick with ABCDE and call for help!
- Practise +++



Examples

Okay-ish (for third year):

I examined the cardiovascular system of G.B a 65 year old gentleman. In the hands, there was no evidence of clubbing, leukonychia, koilonychia or splinter haemorrhages. There was some corneal arcus in the eyes. I then examined for the JVP which was normal. On the chest, the apex beat was found in the 5th intercostal space in the mid-clavicular line and the heart sounds were normal except for an ejection systolic murmur that seemed loudest in the aortic region. Examining the chest, I think there was some fine inspiratory crackles at the bases. The patient also had some ankle oedema.

Better for Finals:

I examined the cardiovascular system of G.B. a 65 year old gentleman. He looked comfortable at rest and there was no evidence of cardiovascular disease in the hands but the patient did have corneal arcus. The JVP was not raised and the apex beat was not displaced. On auscultation of the chest, I detected heart sounds 1 and 2 and an ejection systolic murmur, loudest in the aortic region with no radiation. On auscultation of the lungs, there was fine inspiratory crackles in both bases to the mid-zones. The patient also had bilateral pre-tibial oedema up to the mid-calf level.

In summary, this is a 65 year old gentleman with an ejection systolic murmur and signs suggestive of heart failure. I would like to perform a full history and examination and then request an ECG, Chest X-ray and echocardiogram.



Examples

Okay-ish (for third year):

I examined the cardiovascular system of G.B a 65 year old gentleman. In the hands, there was no evidence of ~~clubbing, leukonychia, koilonychia or splinter haemorrhages~~. There was some corneal arcus in the eyes. ~~I then examined~~ for the JVP which was normal. On the chest, the apex beat was found in the 5th intercostal space in the mid-clavicular line and the heart sounds were normal except for an ejection systolic murmur that seemed loudest in the aortic region. Examining the chest, I think there was some fine inspiratory crackles at the bases. The patient also had some ankle oedema.

Better for Finals:

I examined the cardiovascular system of G.B. a 65 year old gentleman. He looked comfortable at rest and there was no evidence of cardiovascular disease in the hands but the patient did have corneal arcus. The JVP was not raised and the apex beat was not displaced. On auscultation of the chest, I detected heart sounds 1 and 2 and an ejection systolic murmur, loudest in the aortic region with no radiation. On auscultation of the lungs, there was fine inspiratory crackles in both bases to the mid-zones. The patient also had bilateral pre-tibial oedema up to the mid-calf level.

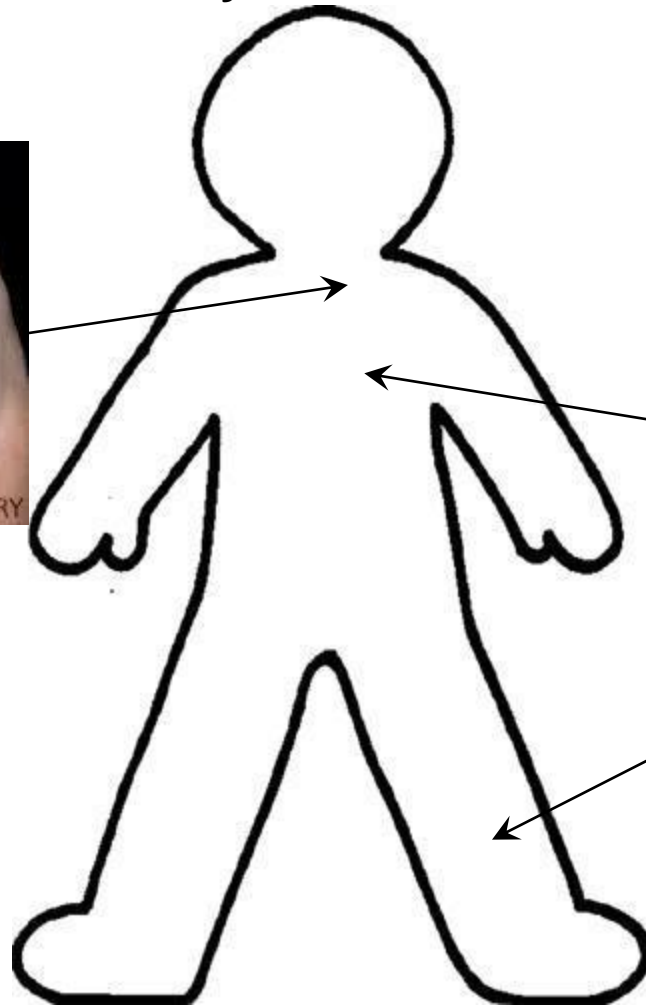
In summary, this is a 65 year old gentleman with an ejection systolic murmur and signs suggestive of heart failure. I would like to perform a full history and examination and then request an ECG, Chest X-ray and echocardiogram.

Why is the second example better?

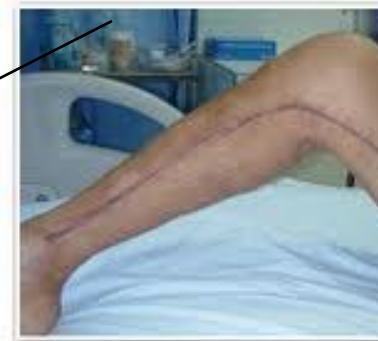

Presentation Practice 1

Examine the CV system of this 75yo



HS I + II + nil



SCIENCEPHOTOLIBRARY

Example Answer

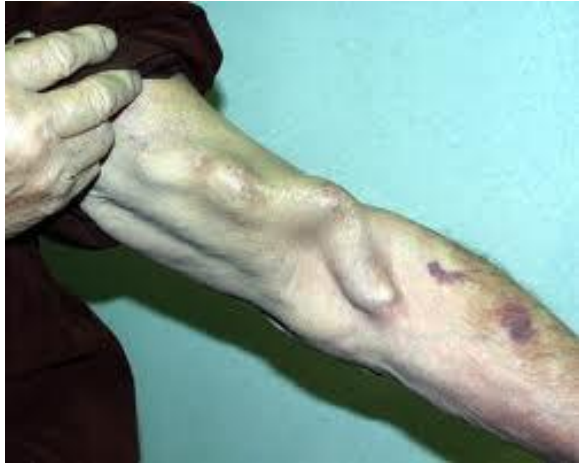I examined the cardiovascular system of this 75 year old man. On general examination, the patient looked comfortable at rest. Of note, he has a high BMI and a mid-line sternotomy scar. He also has a scar on the right leg consistent with a saphenous vein harvest.

The JVP was not raised and on examination of the praecordium, the apex beat was not displaced and the heart sounds were normal and the lung fields clear.

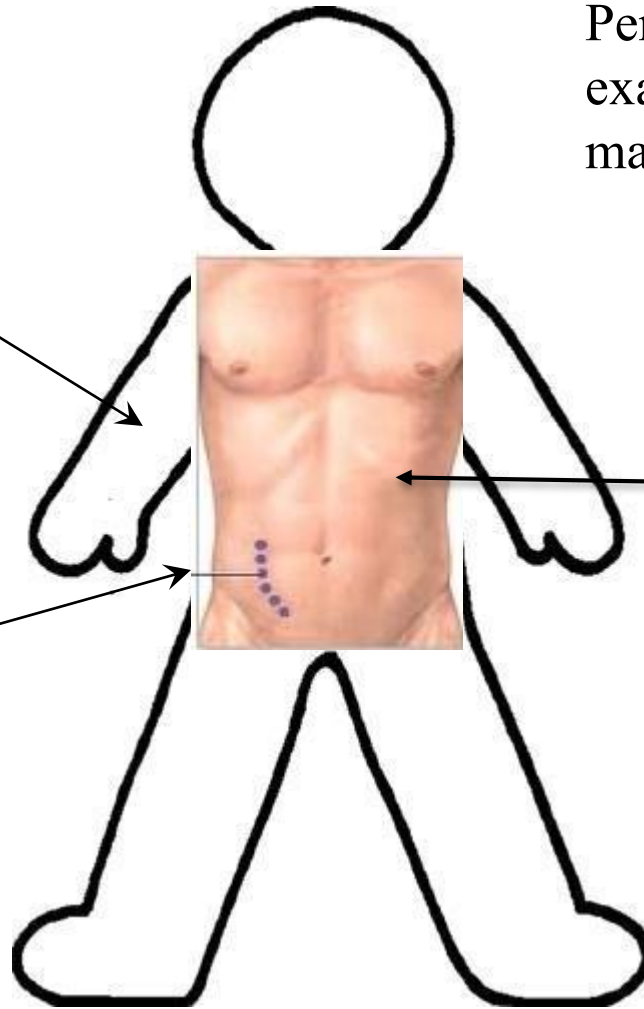
In summary, I examined this 75 year old man who has evidence of a previous coronary artery bypass graft but seems clinically well. To complete my examination, I would like to perform a full history and examination and perform an ECG.



Presentation Practice 2



Scar
+
12cm mass



Perform an abdominal
examination of this 45 yo
man

Soft,
non-tender.
BS normal

Example Answer

I examined the abdominal system of this 45 year old man. On general examination, the patient seemed comfortable at rest and had an arterio-venous fistula in the left arm.

Inspection of the abdomen identified a scar in the right iliac fossa. Underlying this was a well defined 12cm firm, non-mobile mass. The rest of the abdomen was soft and non-tender and bowel sounds were normal. There was no hepatosplenomegaly.

In summary, this 45 year old man appears clinically well but has evidence of renal disease and has likely undergone a renal transplantation. I would like to complete my examination by performing a full history and examination and taking some routine blood tests including U+Es.



History Presentation Practice 1

Gladys Hart, a 75 year old lady presenting with recurrent falls. The falls usually occur in the morning when she gets up from bed. Before falling, she often feels a bit dizzy. She thinks she loses consciousness as the next thing she knows is waking up on the floor. She hasn't injured herself. She has no palpitations or chest pain. She is never incontinent and hasn't bitten her tongue.

She is otherwise well. No recent weight loss, bowels are regular, no urinary symptoms. No headaches.

She lives alone in a bungalow and has twice a day carers. She is a non-smoker and has an occasional glass of sherry.

She has a past medical history of hypertension and takes Ramipril, Bendroflumethiazide and Amlodipine. She is allergic to penicillin.



Example Answer

Gladys Hart is a 75 year old lady presenting with recurrent falls. She has a past medical history of hypertension and is on 3 anti-hypertensives.

The falls occur in the morning when she gets up from bed. Before the fall she feels dizzy and remembers regaining consciousness on the floor. There are no other preceding symptoms. She is otherwise well with no other symptoms.

She lives alone in a bungalow and has twice a day carers. She is a non-smoker and drinks a few units of alcohol a week. She has no allergies.

In summary, this is a 75 year old lady presenting with recurrent falls. My differential diagnosis is postural hypotension secondary to antihypertensive use, alternatively she may have an underlying cardiac arrhythmia. I would like to undertake a full examination, a lying-standing BP and an ECG. Routine bloods including an FBC, U+Es and TFTs would also be useful.



History Presentation Practice 2

Gregory Howell is a 56 year old gentleman. He is presenting with a 2 week history of PR bleeding. He has also become more constipated than usual.

He has noticed that he has lost some weight, approximately 10kg, over the last few months and is feeling more tired than usual. He has no respiratory problems, no headaches nor urinary symptoms.

He currently works as a policeman and smokes 20 cigarettes a day, having done so for the last 25 years. He drinks a bottle of wine every weekend. He lives with his wife and two children.

He takes a statin for his cholesterol but no other medication. He has no allergies.



Example Answer

Gregory Howell is a 56 year old gentleman presenting with a 2 week history of PR bleeding. He also reports constipation and has lost 10kg of weight over the last few months.

He currently works as a policeman and has a 25 pack year smoking history and drinks approximately 10 units of alcohol a week. He lives with his wife and two children.

He takes a statin for his cholesterol but no other medication. He has no allergies.

In summary, this 56 year old gentleman who smokes has presented with a 2 week history of PR bleeding, constipation and weight loss. My primary differential diagnosis is of a GI malignancy, but simple constipation and haemorrhoids is a possibility. I would like to perform a full examination, including a digital rectal examination, perform routine bloods including an FBC, U+Es and LFTs and discuss the case with a specialist in view of performing an endoscopy.



Other Resources

Communication Skills: Breaking Bad News and Explaining

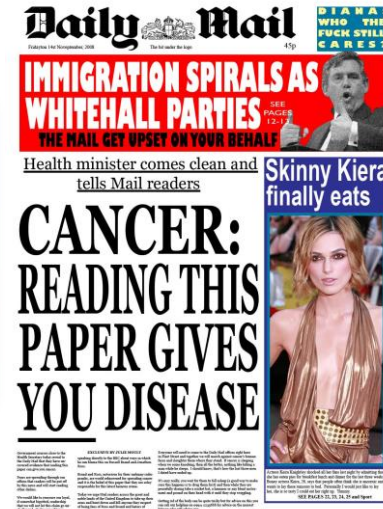Slides available online at:

<http://tinyurl.com/bbn-explaining>

The lecture recording is available at:

<https://tinyurl.com/video-bbn>

(Starting at 27 minutes 52 seconds)



An Overview of the General Examination and Clinical Signs

Presentation available to view at:

<http://tinyurl.com/generalexamination>



Summary

- Summarising and presenting your findings should become a routine part of your revision
- SBAR can be utilised in many situations as a framework for communication
- Keep things simple and relevant
- Have a quick list of ‘go to’ investigations for each system



THANK-YOU

Any Questions?

